

Countway Library Interlibrary Loan



ILLiad TN: 3999573

Borrower: NYUHSS

Lending String:

Patron: Altman, Emily

Journal Title: Acta chirurgiae orthopaedicae et
traumatologiae Cechoslovaca

Volume: 78 **Issue:** 5
Month/Year: 2011 **Pages:** 395-403

Article Author: Neuhaus V; Jupiter J

Article Title: Current concepts review: carpal
injuries - fractur

Imprint:

ILL Number: 33641654



COPYRIGHT NOTICE

The copyright law of the United States (title 17, United States Code) governs the making of photocopies or other reproductions of copyrighted material. Under certain conditions specified in the law, libraries and archives are authorized to furnish a photocopy or other reproduction. One of these specific conditions is that the photocopy or reproduction is not to be 'used for any purpose other than private study, scholarship, or research.' If a user makes a request for, or later uses, a photocopy or reproduction for purposes in excess of 'fair use,' that user may be liable for copyright infringement. This institution reserves the right to refuse to accept a copying order if, in its judgment, fulfillment of the order would involve violation of copyright law.

Call #:

Location:

Email (PDF) To: medlib@hss.edu
Charge
Maxcost: \$12.00

Shipping Address:
Hospital for Special Surgery
Barrett Memorial Library ILL Department
535 East 70th Street
New York, NY 10021-

Odysseys:
Ariel:

PDF

Current Concepts Review: Carpal Injuries – Fractures, Ligaments, Dislocations

Souborný referát. Karpální poranění – zlomeniny, vazy, dislokace

V. NEUHAUS, J. B. JUPITER

Hand and Upper Extremity Service, Massachusetts General Hospital, Orthopaedic Surgery, Boston, Massachusetts, 02114, USA

SUMMARY

An overview about current concepts in treating carpal injuries is presented. These injuries are more commonly seen in young, active individuals after a fall on an outstretched hand. Conventional radiographs and a thorough examination are important. The scaphoid is the most affected bone. Scaphoid fractures can be classified in accordance to OTA, AO, and other classification systems, but mostly to Herbert. It can be treated non-operatively if undisplaced, however a percutaneous internal fixation can be discussed to achieve earlier return to work and shorter time to union, but hazarding the consequences of an operation. Unstable, proximal pole, or delayed diagnosed scaphoid fractures should be treated surgically. Nonunion is seen in 5 - 40% of scaphoid fractures depending mainly on displacement and localization of the fracture. The gold standard in non-osteoarthritic scaphoid nonunion is debridement of the nonunion site, bone grafting, realignment, stable fixation and rehabilitation. The treatment of scaphoid-nonunion advanced collapse is more complex. Proximal row carpectomy or arthrodesis (four-corner or complete wrist) can be mandatory. Other carpal bone fractures are rare. Perilunate dislocations are also uncommon but can be disabling. They usually originate in high-energy trauma. The Mayfield stages help to understand the injury pattern. Open reduction through both volar and dorsal approaches, repair of the volar capsule as well as volar and dorsal ligaments, and internal fixation is commonly the standard treatment. However osteoarthritis and carpal instability are often encountered.

Key words: carpal; concepts; current; dislocations; fractures; injuries; ligaments; review.

INTRODUCTION

Carpal injuries are more often encountered in young, active people. In most instances, the main mechanism is a fall on an outstretched hand. The diagnosis at times may be challenging. Therefore the incidence and prevalence of carpal injuries are not clear. The scaphoid fracture represents 70 - 90% of all carpal bone fractures (20,38). The incidence of scaphoid injuries can be as high as 120 in 100'000 person-year (41,46). Carpal dislocations are clearly less frequently encountered with trans-scaphoid perilunate fracture dislocations found in up to 61% of all perilunate dislocations (17). The treatment of carpal injuries can be very demanding and can have a long-term effect on young patients. We therefore want to give an overview of our current concepts.

Acute fractures of the scaphoid

Establishing the diagnosis

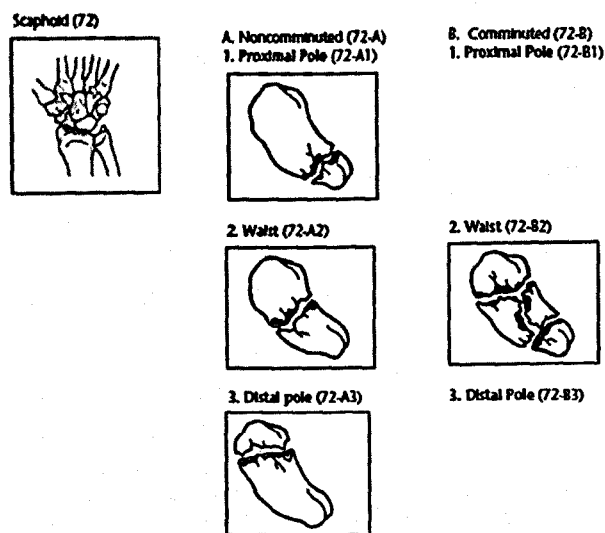
The patients seek medical advice usually after a fall on an outstretched hand. They complain of acute wrist pain. There may be some amount of local swelling and tenderness in the anatomic snuffbox. Pain on compression and painful pinch grip can be elicited. However all

these tests are not reliable to confirm the diagnosis. Other upper extremity findings must be ruled out. Every patient complaining of wrist pain after a fall must have adequate standard radiographs. We usually get four views (PA, lateral, semi-pronated, and semi-supinated). Nearly 70% of all scaphoid fractures will be detected on initial radiographs (3). If the fracture is not visible on the initial radiographs and there is a strong suspicion of a fracture, called **suspected scaphoid fractures**, one to two weeks of immobilization is recommended, followed by a repeat x-ray series. MRI, bone scanning, CT, and ultrasound may be useful to rule out true fractures. CT and MRI are comparable. Mallee and his colleagues stated, that "both were better at excluding scaphoid fractures than they were at confirming them, and both were subject to false-positive and false-negative interpretations" (24). The sensitivity of CT and MRI can be as low as 67%, whereas the specificity is usually higher than 90%. Bone scanning shows a sensitivity reaching nearly 100%.

Fracture classification

Noncomminuted and comminuted (more than three fragments) fractures are distinguished in the OTA clas-

Diagram 1. OTA-classification of scaphoid fractures



sification (Diagram 1; <http://www.ota.org/compendium/compendium.html>). The localization of the main fracture is also differentiated: proximal pole, waist, distal pole. Similar classification systems are introduced by Russo or Mayo, based on the fracture line. The AO classification of the scaphoid, introduced by Petravic and Siebert 1989, distinguishes type A (avulsed or chip), type B (simple, oblique, or longitudinal through the body), and type C (comminuted) fractures (28). Management of acute scaphoid fractures should ideally be oriented on the concept of fracture stability, associated ligamentous injury, and risk of impaired blood supply, rather than the direction of the fracture line or location of the fracture within the scaphoid (18). Herbert takes stability into account and therefore classified scaphoid fractures in four subgroups (16):

Type A: acute "stable" fractures

Type B: acute "unstable" fractures

Type C: delayed union

Type D: established nonunion

Oblique fractures of distal third, displaced fractures of waist, proximal pole fractures, fracture dislocations of the carpus and comminuted fractures are according to Herbert unstable fractures.

But the inter- and intraobserver reliability of all these classification systems is probably low.

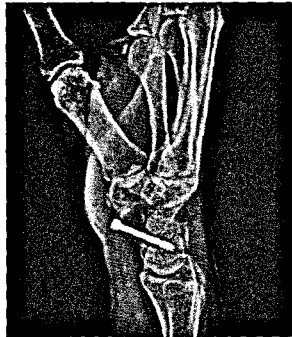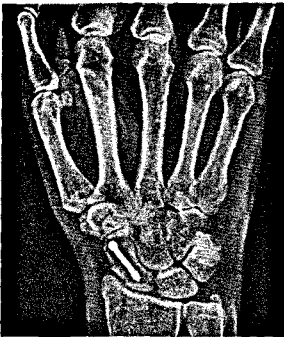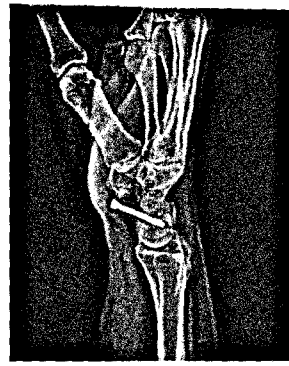
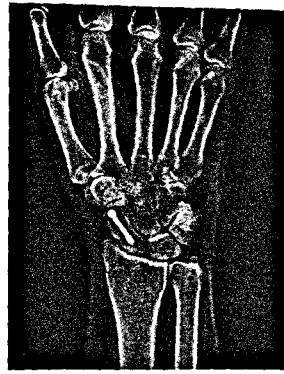
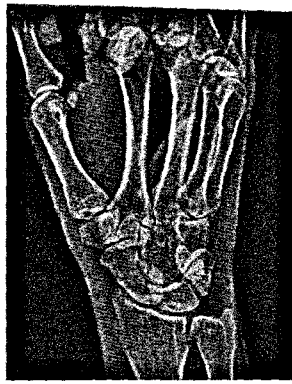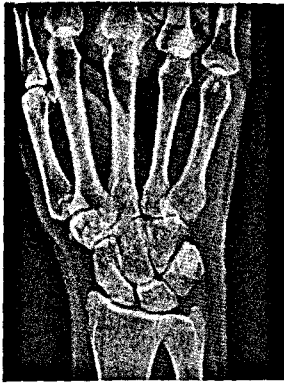Treatment

Isolated undisplaced scaphoid fractures can be treated with cast immobilization. Clay et al. had an overall healing rate of 84% in stable scaphoid fractures (7). Schädel-Höpfner treated 37 patients with an undisplaced scaphoid fracture conservatively (33). Two of them showed a delayed union: one of them healed with additional immobilization, and one healed after bone grafting. Vinnars et al. presented one delayed union, treated operatively, in a group of 35 patients (43). The type of cast is under debate. Gellman et al. performed a small randomized controlled trial to answer this question (13). They recommended an initial period of six weeks of

immobilization in a long thumb-spica cast, followed by use of a short thumb-spica cast, in accordance to other authors (12). They could show that time to union is shorter in the above the elbow cast group without any loss of motion of the elbow. Also Verdan supports this treatment while citing cadaver studies showing motion at a scaphoid osteotomy while pronation and supination of the forearm (42). We prefer a short arm thumb-spica cast, as other authors (33), fearing stiffness of the elbow. There exist questions as to the need for including the thumb in the cast, however there seems to be no difference in both groups for development of nonunion (7). The cast can be removed as soon as union is established. The time of immobilization is dependent upon radiographic union. Confirmation of a healed fracture can be done clinically (no local tenderness and no pain with motion) and radiographically. Yet the presence of union on radiographs can be difficult. Dias et al. found poor inter-observer agreement and reproducibility to assess the rate of union in radiographics (10). CT can greatly help to assess the process of healing. Hackney and Dodds suggest that most surgeons prefer to see at least 50% bridging bone prior to releasing patients to full activities (15).

Casting can lead to stiffness, muscular atrophy, and disuse osteoporosis (11). Improved healing rates in a shorter time and earlier rehabilitation (and earlier return to work) with percutaneous techniques of internal fixation have produced a clear shift from classic conservative treatment to internal skeletal fixation (Figures 1A – 1F) (26, 33). McQueen et al. reported in a prospective study time to union to be 9.2 weeks in the operated groups whereas 13.9 weeks in the conservative treated patients. After three months 53% of patients are back at full work in conservatively treated patients, whereas 84% of surgically treated patients already started to work (33). Vinnars et al. showed no difference in time off work for nonmanual workers (43). Dias et al. also reported a better range of movement and grip strength in the first 3 months in the operated group (11). But after 6 months there were no significant differences. Surgical treatment can also be assorted with complications (47). Hematoma, wound issues, infections, malpositioning of screws, and implant related complications have been reported (43). In the long-term follow-up (10 years) there is also a higher risk of scaphotrapezial osteoarthritis following distal to proximal screw fixation (43). Thus, the long-term risks, short-term benefits, and the costs of surgery should be carefully weighted (5,43). If screw fixation is used, after 2 weeks we usually go to a removable splint for another 6 weeks and tell the patients to avoid such as pushing against or lifting heavy objects.

Proximal pole fractures are prone to delayed or nonunion due to the unique blood flow in the scaphoid. Clay et al. identified only 59% of proximal pole fractures to have healed following non-operative treatment (7). The main source of blood supply enters at the distal and dorsal non-articulating surface area of the scaphoid producing a retrograde blood flow to the proximal pole. This may lead to healing problems as well as



a | b | c | d
e | f

Figures 1A – 1F. An undisplaced scaphoid waist fracture treated with percutaneous internal fixation in a young and active patient. After 6 months the fracture was healed. The patient was painfree and had excellent function.

increased motion at the fracture site. Stable internal fixation is therefore indicated in proximal pole fractures to provide mechanical stability and enhance fracture surface contact to enhance revascularization (18). They are best managed through a dorsal approach due to easier accurate screw placement.

Initially **unrecognized** and untreated **scaphoid fractures** lead more often to nonunion (39). Therefore most authors recommend internal fixation of scaphoid fractures diagnosed after four weeks (30).

It is crucial to differentiate **displaced** and **undisplaced fractures**, but this can be difficult from standard radiographs. In a cadaver study Bernard et al. concluded that conventional radiography is not reliable in determining 1-mm displacement and showed a lack of strong interobserver agreement (2). In case of a fracture we therefore recommend a CT scan to rule out displacement (22). Displacement can be defined as a gap of one millimeter between the fracture fragments, a 10-degree change in the lateral and anteroposterior intrascaphoid angles, or a height-to-length ratio of the scaphoid of 0.65 or more (9). Trumble and his colleagues suggested that displaced fractures tend to be slower to heal, require a longer duration of immobilization, and are associated with a higher risk of post-traumatic osteoarthritis (40). Additionally, displaced fractures will have a much higher rate of nonunion or malunion. Displaced or unstable fractures are therefore usually an indication for closed or open reduction and internal fixation (9,16). They can be fixed either via a volar or dorsal approach. Distal and waist fractures are best approached from the volar side. A Herbert or a cannulated AO/AISF screw is usually used. Independent of the fixation technique a more central positioned screw lead to shorter time to union (39). Time to union in operatively treated displaced scaphoid frac-

tures range from three to 5.4 months (40). Nearly 100% heal uneventful (16,40).

Surgical approaches:

All the operations are performed on a hand table. A nonsterile pneumatic tourniquet is usually used. Prophylactic antibiotics are optional. Anesthesia is general or regional.

Percutaneous technique: This technique can be performed either proximal to distal or distal to proximal depending on the fracture localization. Under image intensification the distal or proximal tip of the scaphoid is explored and the guide wire inserted.

Volar approach: A modified Henry approach is usually preferred. Under protection of the palmar cutaneous branch of the median nerve the flexor carpi radialis sheet is opened and the thenar muscles are splitted in line. Afterwards the volar radiocarpal ligaments and capsule can be incised to expose the scaphoid.

Dorsal approach: The forearm is pronated on a hand table. A dorsal oblique incision provides good access to the scaphoid and the distal radius for harvesting of bone graft. The interval between the third and fourth compartment is exposed and the capsule is opened in line with its fibers.

In diagram 3 pictures of the implants are provided.

Outcome and complications

Nonunion is noted to occur from 5 - 40% of all treated scaphoid fractures, mainly depending of displacement and localization of the fracture (11,16,26). Nonunion can lead to humpback deformity with palmar rotation of the distal fragment, carpal collapse and osteoarthritis. Mack et al. reviewed the natural history of scaphoid nonunions clinically and roentgenographic (23). They found three

roentgenographic patterns: sclerosis, cyst formation, or resorptive changes confined to the scaphoid bone – also called scaphoid-nonunion advanced collapse (SNAC) wrist – after an average of 8 years; radioscaphoid arthritis after 17 years; and generalized arthritis after more than 30 years. Fracture displacement and carpal instability correlated with the severity of degenerative changes. The patients will present with complaints of pain, swelling, weakness, stiffness and loss of strength. According to Prosser and Barton there are some typical patterns of presentation (1, 29):

1. Patients having a scaphoid fracture treated non-operatively with a cast for 6 weeks and discharged of further treatment (inadequate follow-up). It was assumed that these fractures had already healed. As mentioned before assessment of healing is difficult. We therefore advocate the use of CT to assure union and further follow-up.
2. Patients having a scaphoid fracture treated non-operatively with a cast for more than 9 weeks and further follow-up (adequate follow-up). Undisplaced scaphoid fractures heal in up to 90% uneventful. But especially displaced and proximal pole fractures can lead more often to nonunion. Also smokers are more prone to nonunion.
3. Patients who were never treated because they did not seek medical attendance. There is probably a considerable amount of undetected nonunions.
4. Patients who have terminated the treatment and removed the cast themselves.
5. The nonunion is discovered coincidentally when radiographs of the hands are taken for other reasons. There is also another group:
6. Patients presenting with a nonunion after internal fixation.

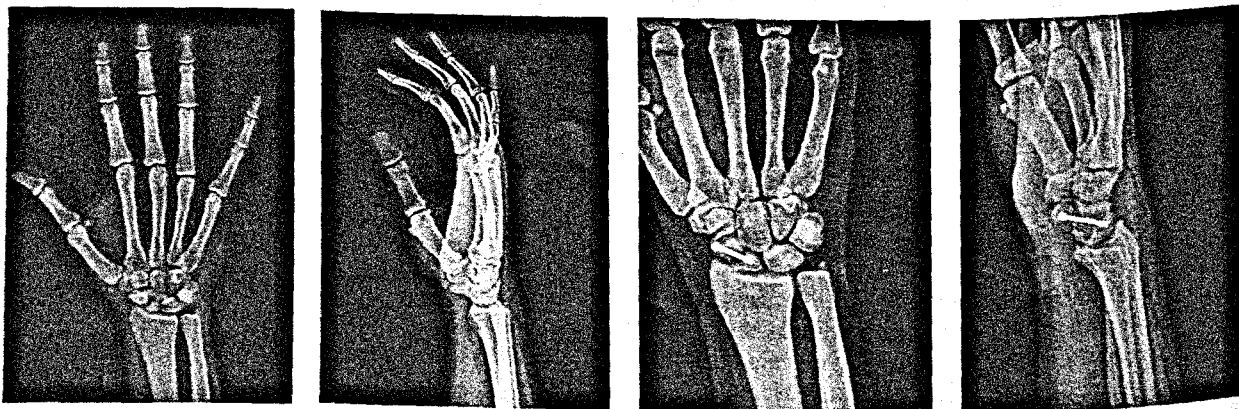
Operative treatment is recommended for the majority of nonunions (Figures 2A – 2D) (16). A preoperative CT scan is helpful to accurately assess the nonunion and the deformity. The standard approach in non-osteoarthritic scaphoid nonunion is debridement of the nonunion site, bone grafting, realignment, stable fixation and rehabilitation with 90% union rates. Matti described the inlay of bone graft, Russe modified the

approach from dorsal to palmar to preserve vascular supply (31). Herbert added internal fixation with a Herbert screw to get primary healing by compression (16). Scaphoid waist nonunions are best treated via a volar approach. In case of a proximal pole nonunion a dorsal approach is preferred. There can be avascular necrosis of the proximal pole. Some authors therefore recommend doing an MRI on a regular basis and assessing the vascular supply of the proximal pole to predict surgical outcome (6, 32). In case of an avascular proximal pole a vascularized bone graft (1,2 intercompartmental suparetinacular artery) is recommended. The union rate of vascularized bone grafts has been reported to be as high as 93% and time to union was around 5 months (44). Salvage procedures include radial styloidectomy, scaphoid ostectomy and fusion of the 2 fragments of the scaphoid to the capitate (Figures 3A – 3F), proximal row carpectomy (PRC) or arthrodesis (four-corner or complete wrist) especially in case of SNAC (23). Strauch reported in a review an active range of wrist motion following four-corner arthrodesis to be about 55% as compared with the opposite side. Most authors prefer PRC due to a better active range of motion (37).

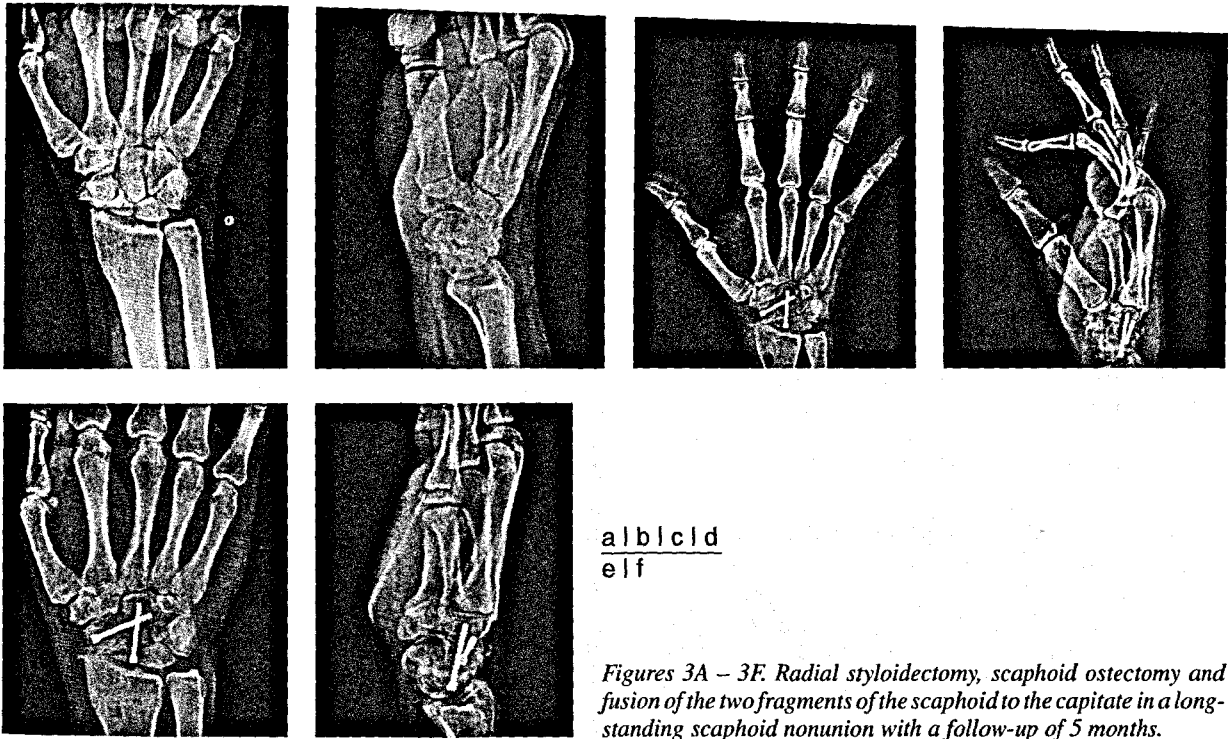
Other carpal fractures

The next most often encountered carpal bone injury is a chip fracture of the **triquetrum**. The incidence range from 4 – 20% of all carpal bone fractures. The mechanism consists of hyperflexion leading to a shearing fracture of the triquetrum due to impingement with the hamate or ulna (27). Another mechanism is the avulsion of the dorsal radiocarpal ligaments during forced palmar hyperflexion. They usually can be treated non-operatively with a cast for 4 – 6 weeks.

Hook of hamate fractures are rare and often related with racket sports. The hand grip can impinge against the hook during a forceful swing and producing a painful fracture (27). Other possible mechanisms are directly applied force in a fall or shearing force applied by flexor tendons (34). They are difficult to recognize on plain radiographs and therefore often delayed or undiagnosed. Due to the attachment of different ligaments and muscles the hook is exposed to shearing forces. There is also



Figures 2A – 2D. A chronic scaphoid nonunion in a 23-year-old male patient handled with open reduction and iliac crest bone grafting, screw fixation, and vascularization with a radial artery pedicle.



a b l c l d
e l f

Figures 3A – 3F. Radial styloidectomy, scaphoid ostectomy and fusion of the two fragments of the scaphoid to the capitate in a long-standing scaphoid nonunion with a follow-up of 5 months.

limited blood supply to the hook. These factors make fractures of the hook prone to nonunion. Fresh undisplaced hook of hamate fracture can be treated non-operatively. Yet the risk of nonunion must be recognized (34). When seen late, patients may present with tendon ruptures or ulnar and median nerve compression. In case of these complications, delayed union or displacement open reduction and internal fixation is a treatment option (35). Most authors however recommend to excise the hook without considerable function impairment, especially grip strength.

Pisiform fractures are as rare as hook of hamate fractures, often undiagnosed and can also cause persistent pain and nerve compression syndromes. Undisplaced fractures can be treated with cast for 4–6 weeks. In case of nonunion or persistent pain excision of the pisiform is the treatment of choice (27).

Fractures of the **body of hamate, capitate, trapezium, and lunate** are rather part of more complex injuries such as fracture dislocations of the carpometacarpal joints, greater arc injuries, or in combinations with other carpal fractures. According to Teisen and Hjarbaek the incidence of fresh lunate fractures are 0.5% of all carpal bone injuries (38). Displaced articular fractures (>1mm) should be treated operatively to minimize risks of complications. Adequate reduction and internal fixation is the standard treatment. K-wires are used in smaller fragments, whereas screws (mini-fragment or Herbert screws) are preferred in bigger fragments.

Ligamentous injuries and dislocations

Establishing the diagnosis

They are uncommon but can lead to profound disability. They are the result of a high-energy hyperex-

tension injury with the wrist in ulnar deviation. Due to the high-energy mechanism concomitant injuries must be ruled out. The patients most often complain of pain. Considerable amount of swelling can be obvious. At least two view of the wrist (posteroanterior and lateral) should be obtained. On a posteroanterior x-ray of the wrist Gilula lines, “Terry Thomas sign”, the triangle shape of the lunate, cortical ring sign of the scaphoid, or diminished carpal height can guide the treating physician. On a lateral view the longitudinal axes of the third metacarpal, capitate, and radius are misaligned. Associated fractures should carefully be assessed. Yet the diagnosis is sometimes not appreciated (17).

Mechanism and dislocation classification

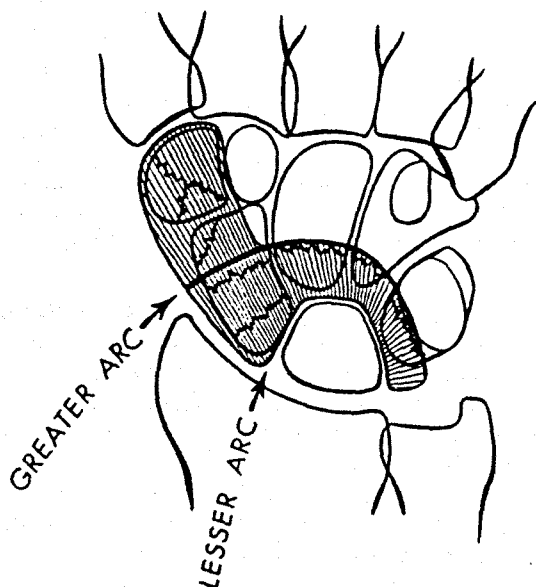
The proximal row is at higher risk for dislocations due to its mobility. Perilunate dislocations follow a predictable circular progression of injury. Mayfield determined four stages of progressive perilunar instability, from the radial to the ulnar side. Each step can occur through either ligament or bone (25). These stages are consistent with observed injury patterns:

- Stage I: The radioscaphoid, scapholunate, and radio-capitate ligaments are torn or attenuated. Radiographs demonstrate scaphoid rotation and scapholunate diastasis.
- Stage II: The capitolunate joint is disrupted, therefore the capitate dislocates in the x-ray.
- Stage III: The palmar radiotriquetral and ulnotriquetral ligaments are torn or attenuated. As a consequence the triquetrum is malrotated or dislocated.
- Stage IV: In the last stage the radiolunate joint is disrupted and the lunate dislocates palmarly.

Green and O'Brien proposed the first classification system for carpal dislocations, consisting of six groups (14). They distinguished the following groups: Dorsal perilunate / volar lunate dislocation; Dorsal transscaphoid perilunate dislocation; Volar perilunate dorsal lunate dislocation; Variants such as transradial styloid perilunate dislocation, naviculocapitate syndrome, transtriquetral fracture dislocation; Isolated rotary scaphoid subluxation, acute and recurrent; Total dislocation of the scaphoid. Mayfield et al. modified this classification system, mentioning four main groups:



- Perilunate dislocations (purely ligamentous, "lesser arc injuries", diagram 2)

Diagram 2. Schema of greater and lesser arc injuries



- Perilunate fracture dislocations ("greater arc injuries", diagram 3)
- Radiocarpal dislocations
- Variants

Diagram 3. Pictures of different scaphoid implants are provided



There are other classification systems (Watson and Jeffrey, Cooney et al.) Cooney et al. mention besides lesser or greater arc injuries and radiocarpal dislocations the following groups (8):

- longitudinal or axial (fracture) dislocations
- isolated carpal bone (fracture) dislocations

The most common encountered dislocations are transscaphoid perilunate fracture dislocations in up to 61% (17).

Treatment

There is lack of evidence in treatment of dislocation injuries. Most of the articles are just case reports or small case series. In the ED closed reduction should be performed as soon as possible. Closed reduction is possible for only a few days after injury (4). In case of open dislocations, acute or progressive carpal tunnel syndrome, or irreducible dislocations direct operation is the only option. Open reduction and internal fixation is the standard treatment (4). Green and O'Brien mentioned five important steps (14). They advise open reduction as soon after injury as is practical, but preferably within 2 weeks.

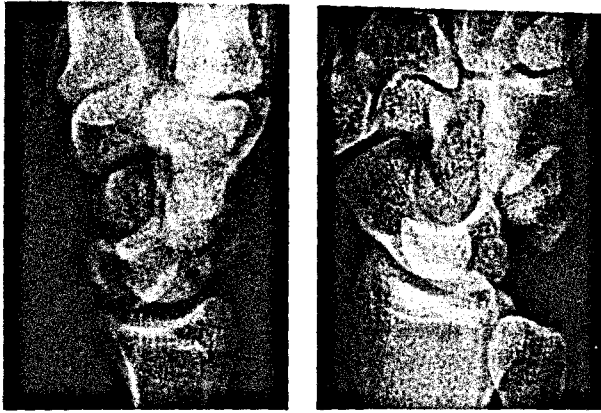
1. expose the carpus through both volar and dorsal approaches. We prefer a dorsal straight incision and exposure of the radiocarpal joint through the third compartment, whereas volar the joint is accessed after a carpal tunnel release. Soft tissue must be carefully preserved.
2. reduce the lunate and repair the volar capsule and ligaments
3. reduce the capitate and scaphoid from the dorsal side and secure the position of all three bones with K-wires (leave in place for 8 weeks and secured with a splint for 12 weeks)
4. repair the dorsal ligaments
5. carefully assess the adequacy of reduction and the position of the pins with radiographs

The results of treatment with temporary screws are comparable to the results of treatment with temporary K-wires (36). It is important that internal stabilization allow the ligaments to heal. Percutaneous and arthroscopic assisted techniques are also described with the key step of closed percutaneous reduction of the carpal fractures (45). Arthroscopy helps to confirm adequate fracture reduction and grade ligamentous injury.

Outcome and complications

Satisfactory results can be achieved (Figures 4A-4F) (19). However osteoarthritis is frequent and increases progressively over time. 50% of the patients show advanced midcarpal arthrosis within four years. Even worse results are presented in the study of Herzberg et al. showing the devastating impact of perilunate injuries (17). Radiologic results do not necessarily correlate with functional outcome. Forli et al. reported progressive osteoarthritic changes but well tolerated after a mean follow-up of 13 years applying the Mayo wrist score.

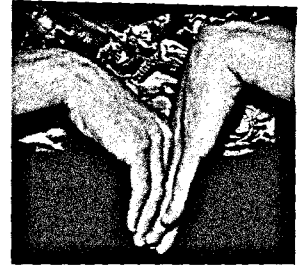
Carpal instability represents disturbance in the anatomical alignment of the articulating carpal bones. This



a b

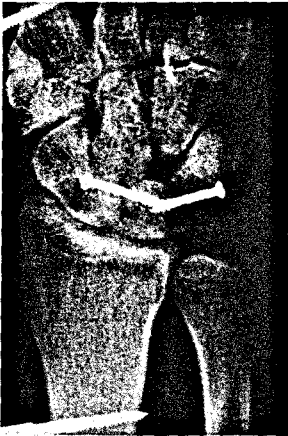

e

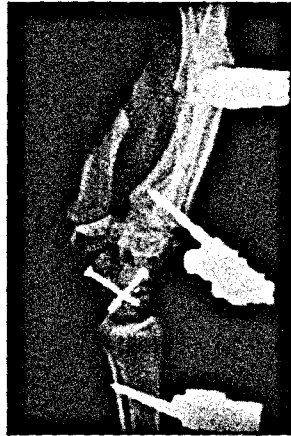

f

Figures 4A – 4F. Perilunate dislocation treated with open reduction, internal fixation, and temporary external fixation with reasonable clinical outcome.



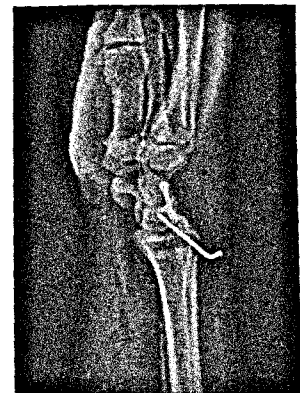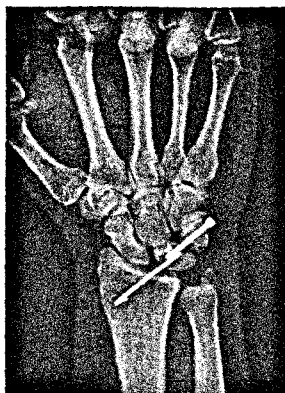
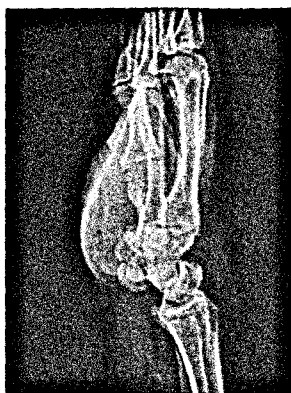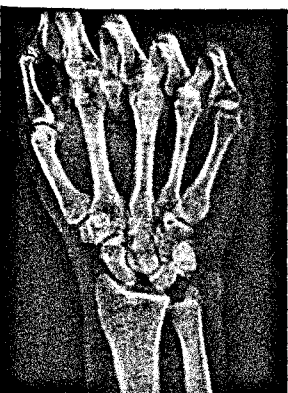
c



d

(carpal instability dissociative, CID) and non-dissociative (CIND), combinations of these two (CIC), and adaptive (carpal instability adaptive, CIA) types. CID types are carpal instabilities caused by dissociation of the bones of just one carpal row. These are mainly the scapholunate ligament tear, lunotriquetral ligament tear, and instable scaphoid fractures in the proximal row. The distal row is usually affected in axial dislocations. Radiocarpal or midcarpal instability with intact intercarpal ligaments build the CIND group. Perilunate or axial pattern injuries are usually a CIC type injury. The direction of instability is the next category to analyze. The most common carpal instability is due to rupture of the scapholunate ligament. In patients with SL-tear the lunate is tilted dorsally and the scaphoid flexed palmarward in the lateral x-ray, leaving the scapholunate angle greater than 80 degrees. This is also called **dorsal intercalated segment instability (DISI)**. **Volar intercalated segment instability (VISI)** is best seen following rupture of the lunotriquetral ligament, whereas the lunate is flexed (Figures 5A – 5D). The scapholunate angle is less than 30 degrees. Other directions (ulnar/radial, proximal/distal, rotatory, or combinations) and numerous surgical techniques are described. Depending on the injury and the amount of arthrosis scapholunate repair, PRC, four-corner arthrodesis, or complete wrist arthrodesis are performed.

disturbed, symptomatic, balance will occur under physiological force. Larsen et al. proposed a way to analyze carpal instability (21). It can be divided in either dynamic (with movement) or already static; acute (less than 1 week), subacute, or chronic (more than 6 weeks) stages. Trauma, degenerative, inflammatory, or other diseases may lead to carpal instability. The malpositioned joint surfaces erode the adjacent bones under increased pressure and lead to secondary osteoarthritis of the wrist. To stop or slow down this irreversible process prompt diagnosis is necessary. There are four different classifications for the pattern. They distinguish dissociative



Figures 5A – 5D. Acute lunotriquetral (VISI) ligament tear in a 56-year-old man approached with open reduction and stabilization of lunotriquetral and midcarpal joint.

References

- BARTON, N. J.: The late consequences of scaphoid fractures. *J. Bone Jt Surg.*, 86-B: 626–630, 2004.
- BERNARD, S. A., MURRAY, P. M., HECKMAN, M. G.: Validity of conventional radiography in determining scaphoid waist fracture displacement. *J. Orthop. Trauma*, 24: 448–451, 2010.
- BHAT, M., MCCARTHY, M., DAVIS, T. R., ONI, J. A., DAWSON, S.: MRI and plain radiography in the assessment of displaced fractures of the waist of the carpal scaphoid. *J. Bone Jt Surg.*, 86-B: 705–713, 2004.
- BUDOFF, J. E.: Treatment of acute lunate and perilunate dislocations. *J. Hand Surg. Am.*, 33: 1424–1432, 2008.
- BUIJZE, G. A., DOORNBERG, J. N., HAM, J. S., RING, D., BHANDARI, M., POOLMAN, R. W.: Surgical compared with conservative treatment for acute nondisplaced or minimally displaced scaphoid fractures: a systematic review and meta-analysis of randomized controlled trials. *J. Bone Jt Surg.*, 92-A: 1534–1544, 2010.
- CEREZAL, L., ABASCAL, F., CANGA, A., GARCIA-VALTUILLE, R., BUSTAMANTE, M., DEL PINAL, F.: Usefulness of gadolinium-enhanced MR imaging in the evaluation of the vascularity of scaphoid nonunions. *AJR Am. J. Roentgenol.*, 174: 141–149, 2000.
- CLAY, N. R., DIAS, J. J., COSTIGAN, P. S., GREGG, P. J., BARTON, N. J.: Need the thumb be immobilised in scaphoid fractures? A randomised prospective trial. *J. Bone Jt Surg.*, 73-B: 828–832, 1991.
- COONEY, W. P., BUSSEY, R., DOBYNS, J. H., LINSCHIED, R. L.: Difficult wrist fractures. Perilunate fracture-dislocations of the wrist. *Clin. Orthop. Relat. Res.*, 214: 136–147, 1987.
- COONEY, W. P., DOBYNS, J. H., LINSCHIED, R. L.: Fractures of the scaphoid: a rational approach to management. *Clin. Orthop. Relat. Res.*, 149: 90–97, 1980.
- DIAS, J. J., TAYLOR, M., THOMPSON, J., BRENKEL, I. J., GREGG, P. J.: Radiographic signs of union of scaphoid fractures. An analysis of inter-observer agreement and reproducibility. *J. Bone Jt Surg.*, 70-B: 299–301, 1988.
- DIAS, J. J., WILDIN, C. J., BHOWAL, B., THOMPSON, J. R.: Should acute scaphoid fractures be fixed? A randomized controlled trial. *J. Bone Jt Surg.*, 87-A: 2160–2168, 2005.
- GELBERMAN, R. H., WOLOCK, B. S., SIEGEL, D. B.: Fractures and non-unions of the carpal scaphoid. *J. Bone Jt Surg.*, 71-A: 1560–1565, 1989.
- GELLMAN, H., CAPUTO, R. J., CARTER, V., ABOULAFIA, A., MCKAY, M.: Comparison of short and long thumb-spica casts for non-displaced fractures of the carpal scaphoid. *J. Bone Jt Surg.*, 71-A: 354–357, 1989.
- GREEN, D. P., O'BRIEN, E. T.: Classification and management of carpal dislocations. *Clin. Orthop. Relat. Res.*, 55–72, 1980.
- HACKNEY, L. A., DODDS, S. D.: Assessment of scaphoid fracture healing. *Curr. Rev. Musculoskelet. Med.*, 4: 16–22, 2011.
- HERBERT, T. J., FISHER, W. E.: Management of the fractured scaphoid using a new bone screw. *J. Bone Jt Surg.*, 66-B: 114–123, 1984.
- HERZBERG, G., COMTET, J. J., LINSCHIED, R. L., AMADIO, P. C., COONEY, W. P., STALDER, J.: Perilunate dislocations and fracture-dislocations: a multicenter study. *J. Hand Surg. Am.*, 18: 768–779, 1993.
- JUPITER, J. B., SHIN, A. Y., TRUMBLE, T. E., FERNANDEZ, D. L.: Traumatic and reconstructive problems of the scaphoid. *Instr. Course Lect.*, 50: 105–122, 2001.
- KREMER, T., WENDT, M., RIEDEL, K., SAUERBIER, M., GERMANN, G., BICKERT, B.: Open reduction for perilunate injuries—clinical outcome and patient satisfaction. *J. Hand Surg. Am.*, 35: 1599–1606, 2010.
- KUDERNA, H.: Fractures and dislocation fractures of the wrist joint. *Orthopade*, 15: 95–108, 1986.
- LARSEN, C. F., AMADIO, P. C., GILULA, L. A., HODGE, J. C.: Analysis of carpal instability: I. Description of the scheme. *J. Hand Surg. Am.*, 20: 757–764, 1995.
- LOZANO-CALDERON, S., BLAZAR, P., ZURAKOWSKI, D., LEE, S. G., RING, D.: Diagnosis of scaphoid fracture displacement with radiography and computed tomography. *J. Bone Jt Surg.*, 88-A: 2695–2703, 2006.
- MACK, G. R., BOSSE, M. J., GELBERMAN, R. H., YU, E.: The natural history of scaphoid non-union. *J. Bone Jt Surg.*, 66-A: 504–509, 1984.
- MALLEE, W., DOORNBERG, J. N., RING, D., VAN DIJK, C. N., MAAS, M., GOSLINGS, J. C.: Comparison of CT and MRI for diagnosis of suspected scaphoid fractures. *J. Bone Jt Surg.*, 93-A: 20–28, 2011.
- MAYFIELD, J. K., JOHNSON, R. P., KILCOYNE, R. K.: Carpal dislocations: pathomechanics and progressive perilunar instability. *J. Hand Surg. Am.*, 5: 226–241, 1980.
- MCQUEEN, M. M., GELBKE, M. K., WAKEFIELD, A., WILL, E. M., GAEBLER, C.: Percutaneous screw fixation versus conservative treatment for fractures of the waist of the scaphoid: a prospective randomised study. *J. Bone Jt Surg.* 90-B: 66–71, 2008.
- PAPP, S.: Carpal bone fractures. *Orthop. Clin. North Am.*, 38: 251–260, vii, 2007.
- PETRACIC, B., SIEBERT, H. R.: Klassifikation der Handskelettfrakturen nach Prinzipien der AO in Müller ME, Nazarian S, Koch P (Hrsg.): AO-Klassifikation der Frakturen. Springer, Berlin Heidelberg New York, 1989.
- PROSSER, G. H., ISBISTER, E. S.: The presentation of scaphoid non-union. *Injury*, 34: 65–67, 2003.
- RING, D., JUPITER, J. B., HERNDON, J. H.: Acute fractures of the scaphoid. *J. Am. Acad. Orthop. Surg.*, 8: 225–231, 2000.
- RUSSE, O.: Fracture of the carpal navicular. Diagnosis, non-operative treatment, and operative treatment. *J. Bone Jt Surg.* 42-A: 759–768, 1960.
- SAKUMA, M., NAKAMURA, R., IMAEDA, T.: Analysis of proximal fragment sclerosis and surgical outcome of scaphoid non-union by magnetic resonance imaging. *J. Hand Surg. Br.*, 20: 201–205, 1995.
- SCHADEL-HOPFNER, M., MARENT-HUBER, M., GAZYKAN, E., TANZER, K., WERBER, K. D., SIEBERT, H. R.: Acute non-displaced fractures of the scaphoid: earlier return to activities after operative treatment. A controlled multicenter cohort study. *Arch. Orthop. Trauma Surg.*, 130: 1117–1127, 2010.
- SCHUEFLER, O., ANDRESEN, R., RADMER, S., ERDMANN, D., EXNER, K., GERMANN, G.: Hook of hamate fractures: critical evaluation of different therapeutic procedures. *Plast. Reconstr. Surg.*, 115: 488–497, 2005.
- SCHUEFLER, O., RADMER, S., ERDMANN, D., GERMANN, G., PIERER, G., ANDRESEN, R.: Therapeutic alternatives in nonunion of hamate hook fractures: personal experience in 8 patients and review of literature. *Ann. Plast. Surg.*, 55: 149–154, 2005.
- SOUER, J. S., RUTGERS, M., ANDERMAHR, J., JUPITER, J. B., RING, D.: Perilunate fracture-dislocations of the wrist: comparison of temporary screw versus K-wire fixation. *J. Hand Surg. Am.*, 32: 318–325, 2007.
- STRAUCH, R. J.: Scapholunate advanced collapse and scaphoid nonunion advanced collapse arthritis—update on evaluation and treatment. *J. Hand Surg. Am.*, 36: 729–735, 2011.
- TEISEN, H., HJARBAEK, J.: Classification of fresh fractures of the lunate. *J. Hand Surg. Br.*, 13: 458–462, 1988.
- TRUMBLE, T. E., CLARKE, T., KREDER, H. J.: Non-union of the scaphoid. Treatment with cannulated screws compared with treatment with Herbert screws. *J. Bone Jt Surg.* 78-A: 1829–1837, 1996.
- TRUMBLE, T. E., GILBERT, M., MURRAY, L. W., SMITH, J., RAFIAH, G., MCCALLISTER, W. V.: Displaced scaphoid fractures treated with open reduction and internal fixation with a cannulated screw. *J. Bone Jt Surg.* 82-A: 633–641, 2000.
- VAN TASSEL, D. C., OWENS, B. D., WOLF, J. M.: Incidence estimates and demographics of scaphoid fracture in the U.S. population. *J. Hand Surg. Am.*, 35: 1242–1245, 2010.
- VERDAN, C.: Fractures of the scaphoid. *Surg. Clin. North Am.*, 40: 461–464, 1960.
- VINNARS, B., PIETREANU, M., BODESTEDT, A., EKENSTAM, F., GERDIN, B.: Nonoperative compared with operative treatment of acute scaphoid fractures. A randomized clinical trial. *J. Bone Jt Surg.*, 90-A: 1176–1185, 2008.

44. WAITAYAWINYU, T., MCCALLISTER, W. V., KATOLIK, L. I., SCHLENKER, J. D., TRUMBLE, T. E.: Outcome after vascularized bone grafting of scaphoid nonunions with avascular necrosis. *J. Hand Surg. Am.*, 34: 387–394, 2009.
45. WEIL, W. M., SLADE, J. F., 3RD, TRUMBLE, T. E.: Open and arthroscopic treatment of perilunate injuries. *Clin. Orthop. Relat. Res.*, 445: 120–132, 2006.
46. WOLF, J. M., DAWSON, L., MOUNTCASTLE, S. B., OWENS, B. D.: The incidence of scaphoid fracture in a military population. *Injury*, 40: 1316–1319, 2009.
47. YIN, Z. G., ZHANG, J. B., KAN, S. L., WANG, P.: Treatment of acute scaphoid fractures: systematic review and meta-analysis. *Clin. Orthop. Relat. Res.*, 460: 142–151, 2007.

Corresponding author:

Jesse B. Jupiter, AO Professor of Orthopedic Surgery,
Hand and Upper Extremity Service,
Yawkey Center, Suite 2100,
Massachusetts General Hospital,
55 Fruit Street, Boston, MA 02114, USA
E-mail: jjupiter1@partners.org