

# Hemi-Hamate Arthroplasty Provides Functional Reconstruction of Acute and Chronic Proximal Interphalangeal Fracture–Dislocations

R. P. Calfee, MD, T. R. Kiefhaber, MD, T. G. Sommerkamp, MD, P. J. Stern, MD

**Purpose** Hemi-hamate resurfacing arthroplasty is a treatment alternative for the management of severe acute and chronic dorsal proximal interphalangeal (PIP) fracture–dislocations. This study was designed to determine whether this procedure would successfully restore function after such injuries.

**Methods** Hemi-hamate reconstructions were performed on 33 patients (mean age, 34 years) who presented to 1 hand surgery practice with dorsal PIP fracture–dislocations. Eligible patients experienced unstable dislocations with comminuted metaphyseal fractures involving at least 50% of the volar middle phalangeal surface that was not amenable to open reduction and internal fixation. We evaluated 22 patients with 14 acute (<6 weeks) and 8 chronic (mean, 30 weeks) injuries at a mean of 4.5 years (range, 1–7 years). Functional outcomes were assessed by objective and subjective measures: joint alignment/motion/stability, grip strength, Disabilities of the Arm, Shoulder, and Hand (DASH) scores, and visual analog scales (VAS) of pain and function.

**Results** After hemi-hamate reconstruction, active PIP motion averaged 70° (acute 71°, chronic 69°) with a mean flexion contracture of 19° (range, 0° to 80°). Active distal interphalangeal motion averaged 54° (acute 56°, chronic 51°). The mean VAS score for digit pain was 1.4 (acute 0.7, chronic 2.5). The mean DASH score of 5 (acute 2, chronic 9) and VAS functional score of 1.9 (acute 1.4, chronic 2.6) indicated little functional impairment (acute 2, chronic 9). Grip strength averaged 95% of the opposite hand. Mean coronal plane angulation at the PIP joint was 3°. Ten patients reported aching with cold temperatures. One dissatisfied patient underwent revision surgery. Chronic reconstructions were associated with increased VAS pain ratings ( $p = .02$ ) and higher DASH scores ( $p = .06$ ).

**Conclusions** Hemi-hamate reconstruction represents a valuable surgical procedure to address severe PIP joint fracture–dislocations. Reconstruction of chronic injuries by this method restores PIP function, albeit with more modest outcome performance. (*J Hand Surg* 2009;34A:1232–1241. Copyright © 2009 by the American Society for Surgery of the Hand. All rights reserved.)

**Type of study/level of evidence** Therapeutic IV.

**Key words** Arthroplasty, dislocation, fracture, hemi-hamate, proximal interphalangeal.

**P**ROXIMAL INTERPHALANGEAL (pip) joint fracture–dislocations are common injuries that can result in persistent stiffness, pain, and angulation.<sup>1</sup> In most cases, the PIP joint dislocates dorsally, fracturing the volar articular surface of the middle phalanx.<sup>1,2</sup> This

injury has been classified according to the amount of articular involvement as well as the degree of flexion required to maintain a concentric reduction<sup>1,2</sup> (Fig. 1). Most injuries that fracture less than 30% of the middle phalangeal surface are stable and can be treated non-

*From the Department of Orthopedic Surgery, Division of Hand Surgery, Washington University School of Medicine, St. Louis, MO; and Hand Surgery Specialists, Inc., and the Department of Orthopedic Surgery, Division of Hand Surgery, University of Cincinnati School of Medicine, Cincinnati, OH.*

Received for publication November 20, 2008; accepted in revised form April 20, 2009.

No benefits in any form have been received or will be received related directly or indirectly to the subject of this article.

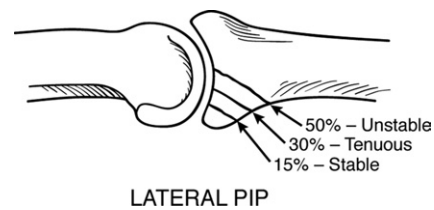
**Corresponding author:** Ryan P. Calfee, MD, 660 South Euclid Avenue, Campus Box 8233 St. Louis, MO 63110; e-mail: calfee@wudosis.wustl.edu.

0363-5023/09/34A07-0009\$36.00/0  
doi:10.1016/j.jhssa.2009.04.027

surgically with extension block splinting. When 30% to 50% of the joint surface is compromised and increasing flexion is required to maintain reduction, surgical stabilization is indicated. Such unstable injuries have been effectively treated with external fixation,<sup>3,4</sup> volar plate arthroplasty (VPA),<sup>5-7</sup> and open reduction and internal fixation (ORIF).<sup>6,8</sup>

Treatment is particularly challenging when over 50% of the PIP joint surface is fractured. With this degree of articular injury, the entire volar bony buttress preventing dorsal PIP subluxation is lost. In cases without comminution, ORIF has been successful, albeit with a higher complication rate than in lesser injured joints.<sup>6</sup> When comminution prohibits internal fixation, VPA has been employed.<sup>1</sup> Complications of VPA include recurrent subluxation, inadequate PIP motion, and distal interphalangeal (DIP) joint stiffness. External fixation has been viewed as a less invasive treatment option, although its effectiveness is contingent on the joint reducing and fracture fragments acceptably aligning under closed traction.<sup>9</sup> Described in 1999 by Hastings et al., the hemi-hamate arthroplasty offers a technically demanding treatment alternative for unstable PIP fracture-dislocations that offers several advantages (Hastings H, Capo J, Steinberg B, et al., presented at the 54th Annual Meeting of the American Society for Surgery of the Hand, 1999, Boston, MA). Replacing the injured middle phalangeal base with the distal articular surface of the hamate allows for treatment of even highly comminuted fractures and recreates the cup-shaped contour of the base of the middle phalanx. In addition, reconstruction with a single osteoarticular fragment allows for internal fixation sufficiently stable for early motion protocols.

To date, we could find 1 peer-reviewed publication that examined outcomes of the hemi-hamate arthroplasty.<sup>10</sup> This series reported on 13 patients at a mean of 16 months (range, 6–43 months). Seven of the 13 patients were observed for less than 1 year. Our current study was undertaken to determine the functional outcomes of hemi-hamate reconstruction in a larger group of patients ( $n = 22$ ) at longer follow-up (mean, 54 months; range, 12–87 months). In addition, the current cohort included 8 patients treated for chronic fracture-dislocations, allowing subgroup analysis based on injury chronicity. In re-examining 5 patients from the original series, the durability of outcomes over a 5-year period was also assessed. Our hypotheses were 2-fold. First, we believed that the early outcomes of hemi-hamate arthroplasty would be maintained over time. Second, we hypothesized that the functional results of



**FIGURE 1:** Diagram of PIP fracture stability as a function of the percentage of joint surface fractured. Reprinted with permission from Calfee RP, Sommerkamp TG. Fracture-dislocation about the finger joints. *J Hand Surg* 2009;34A:1140–1147.

acute reconstructions would be superior to those obtained for chronic injuries.

## MATERIALS AND METHODS

We obtained institutional review board approval before the study's inception. This investigation was designed as a retrospective case series to evaluate the outcomes of hemi-hamate arthroplasty for dorsal PIP joint fracture-dislocations. All patients having undergone hemi-hamate arthroplasty were identified by a computerized database search. We identified 33 patients (19 men and 14 women) who had been treated by 1 of 5 surgeons between July 1998 and January 2007. Of these 33 patients, 11 were among those studied by Williams et al.<sup>10</sup> For inclusion, patients were required to have at least 1 year of follow-up, have suffered PIP dislocations with isolated metaphyseal fractures involving at least 50% of the volar PIP articular surface of the middle phalanx, and be mentally competent. Three patients were excluded from the study. One patient was in a group home environment for psychiatric illness and 2 patients had diaphyseal fracture extension into the middle phalanx. Those patients with diaphyseal fractures were thought to represent a nonstandard, expanded indication for hemi-hamate arthroplasty and are presented in the Discussion section. At the time of this study, 1 patient had undergone a salvage procedure. This patient is included as a treatment failure. His current motion and expressed satisfaction were not included in data analysis because it reflected a silicone arthroplasty as opposed to a hamate autograft. The remaining 29 patients were eligible for study inclusion and data analysis.

Seven patients were lost to follow-up. One was on active military deployment, 1 was currently indigent and had lost contact with his next of kin, and 1 was believed to be incarcerated. We failed to locate 4 patients for follow-up despite multiple attempts by mail and phone. Table 1 shows that those patients lost to follow-up or unable to be evaluated objectively for this

**TABLE 1. Comparison of Study Cohort and Patients Unable to Be Reassessed Objectively**

	Patients With Objective Data (n = 20)	Patients Without Objective Data* (n = 11)
Age (y) (range)	35 (14–62)	29 (17–55)
Dominant involvement (%)	10 (50)	4 (40)
Acute:chronic reconstruction	12:8	7:4
% Joint involvement (range)	62 (50–90)	63 (50–75)
PIP extension (range)†	19° (0°–80°)	9° (0°–25°)
PIP flexion (range)†	89° (45°–105°)	86° (65°–100°)
PIP arc (range)†	70° (0°–100°)	77° (45°–100°)

\*Includes 7 lost to follow-up, 2 with subjective follow-up only, 1 patient salvaged, and 1 unable to consent for study.

†For patients without objective data, this was determined from latest recorded motion  $\geq 1$  month postoperatively.

study were similar to the study population in terms of joint involvement and early postoperative PIP motion. All of these patients had been observed by their surgeon for less than 1 year, which prohibited their inclusion by chart review. Among the initial 13 patients presented by Williams et al.,<sup>10</sup> 5 returned for a re-examination, 2 were included by chart review, and 1 was excluded on the basis of his psychiatric illness. Despite multiple attempts, 3 patients were lost to follow-up and 2 could not be identified in our database searches.

Therefore, 22 of 29 eligible patients were included in our study. The mean follow-up was 4.5 years (range, 1–7 years). The 13 male and 11 female patients had a mean age of 34 years (range, 14–63 years) at the time of surgery. Objective outcome measures were recorded in 20 patients (16 return examinations, 2 chart reviews, and 2 via photographs of digital motion). Photographs used to assess digital motion were based on templates provided to the patients. These included a dorsal view of the hand with all digits extended, and lateral views of the affected digit in full active extension and maximal flexion. Consequently, 20 patients contributed data to our assessment of postoperative motion, whereas 18 patients were assessed for joint stability, sensibility, tenderness, and grip strength. For the 2 patients included by chart review, the final follow-up occurred at 2 and 3 years, respectively. Those 2 patients included by chart review did not complete patient-rated outcome measures.

Table 2 details this cohort's injury patterns. Having a

**TABLE 2. Injury Patterns**

Injury mechanism (no. of patients)	
Sports	13
Fighting	3
Fall	4
Motor vehicle accident	1
Work	1
Injured digit (no. of patients)	
Index	1
Middle	6
Ring	13
Small	2
Mean joint involvement (range)	
Entire cohort (n = 22)	63% (50%–90%)
Acute injuries (n = 14)	63% (50%–80%)
Chronic injuries (n = 8)	61% (50%–90%)

softball or baseball axially impact the distal end of the extended digit accounted for 8 of 22 injuries. The dominant hand was injured in 11 of 22 injuries. Two patients suffered concomitant injuries to the affected digit: 1 bony mallet and 1 distal phalanx shaft fracture (both managed nonsurgically).

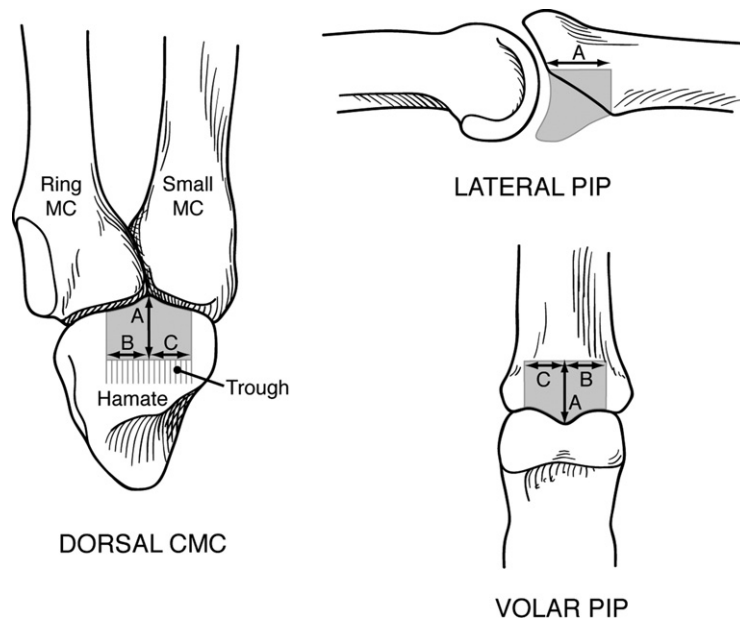
Joint involvement was estimated from direct intraoperative measurement. When not recorded in the surgical report, the joint involvement was calculated by measuring the height of the intact dorsal cortex versus the height of the fractured volar surface. If comminution prohibited measurement, the percent involvement was determined from the height of the intact dorsal cortex compared with the height of an adjacent (non-fractured) middle phalanx on preoperative radiographs. This was performed with calipers measuring to the nearest millimeter.

Fourteen patients were treated acutely (<6 weeks), whereas 8 patients presented with chronic injuries. The chronic reconstructions occurred at a mean of 30 weeks and a minimum of 9 weeks after the injury. The mean preoperative PIP arc of motion in those with chronic injuries was 39° (range, 10° to 76°). One patient in the chronic cohort had a previous surgery (failed VPA).

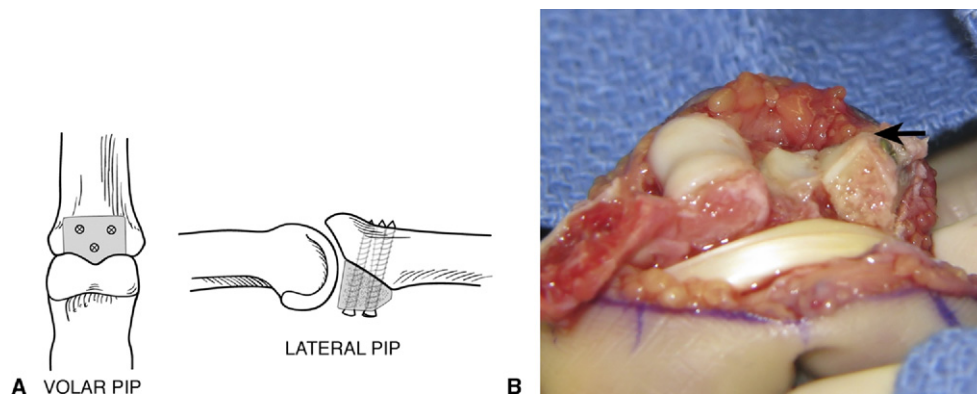
### Surgery

The surgical technique of hemi-hamate reconstruction has been described in detail previously.<sup>10</sup> All primary surgeons in this series perform the procedure similarly and follow the same postoperative protocol.

As our experience has grown, the authors have routinely performed an extensor tenolysis during recon-



**FIGURE 2:** Diagram of middle phalanx defect and corresponding hamate donor site. **A** Proximal–distal length of the autograft corresponding to the distal extent of the fracture from the PIP joint into the middle phalanx. **B, C** Radial and ulnar width of the autograft to match the middle phalanx defect. CMC, carpometacarpal joint; MC, metacarpal.



**FIGURE 3:** **A** Illustration demonstrating hamate autograft secured, canting it to restore buttress with flatter surface. **B** Intraoperative view of restoration of volar buttress (hamate autograft marked with arrow). **Figure 3B** reprinted with permission from Calfee RP, Sommerkamp TG. Fracture–dislocation about the finger joints. *J Hand Surg* 2009;34A:1140–1147.

structions of chronic cases. We believe this assists in restoring lost motion. Also, in all cases a trough is made in the hamate proximal to the intended graft to assist in harvesting a graft of uniform thickness from the dorsal half of the distal hamate (Fig. 2). The fragment is then seated into the middle phalanx, taking care to cant the graft to restore the volar buttress with the hamate autograft, which is relatively flat in the sagittal plane (Fig. 3). The graft is secured with 2 to 3 screws (1.0–1.5 mm). Screws are placed bicortically but not overdrilled as in true compression screws.

Postoperatively, range of motion exercises are initiated by 1 week. A 15° dorsal blocking splint is applied.

Patients are fitted with elastic garments for edema control. At 6 weeks postoperatively, protective splints are discontinued and passive range of motion is begun.

#### Outcome measures

Active and passive arcs of motion of the injured digit's metacarpophalangeal, PIP, and DIP joints were recorded with a goniometer. The reconstructed PIP joints were manually evaluated for tenderness as well as coronal and sagittal stability. Circumference of the PIP joint was measured to the nearest millimeter and compared with the corresponding contralateral PIP joint. Two-point discrimination was assessed on the radial and

**TABLE 3. Objective Outcome Measures**

Outcome	Mean (range)
PIP flexion	89° (45°–105°)
PIP extension	19° (0°–80°)
PIP arc	70° (0°–100°)
PIP circumference % contralateral	103% (95%–122%)
PIP coronal deviation	3° (0°–12°)
DIP arc	54° (0°–85°)
Grip % contralateral	95% (75%–122%)

ulnar borders of the digit using a Discriminator (Mackinnon-Dellon, Baltimore, MD). Bilateral grip strength measurements were made with a dynamometer (Jamar, Boling Brook, IL). We recorded wrist range of motion and assessed hamate donor sites for tenderness. Reconstructed PIP joints were imaged with plain radiographs in 2 planes (posteroanterior and lateral).

Patients were questioned regarding residual pain, cold intolerance, and the sensation of instability in the affected hand and digit. The Disabilities of the Arm, Shoulder, and Hand (DASH) survey was completed to quantify residual functional impairment.<sup>11</sup> Visual analog scale (VAS) ratings (0–10) for both digital pain and function were collected, with higher numerical rating indicating poorer outcome.

### Statistics

We analyzed our data to compare the outcomes between PIP joints reconstructed acutely and those treated for chronic injuries. Grip strength measurements were normally distributed and analyzed with Student's *t*-test. DASH, PIP arc of motion, and VAS of digital function data was non-normally distributed and analyzed by Wilcoxon rank sums scores. VAS ratings of digital pain were non-normal with unequal variance requiring analysis with Fisher's exact test. We used Spearman correlation analysis to evaluate the impact of the percentage of joint surface involvement on each outcome variable.

We performed a *post hoc* power analysis to determine the number of patients needed in each group to detect clinically significant differences adequately in VAS of digital pain, VAS of digital function, and PIP arcs of motion.

### RESULTS

Table 3 summarizes the objective outcome measures for this cohort. All PIP joints examined were

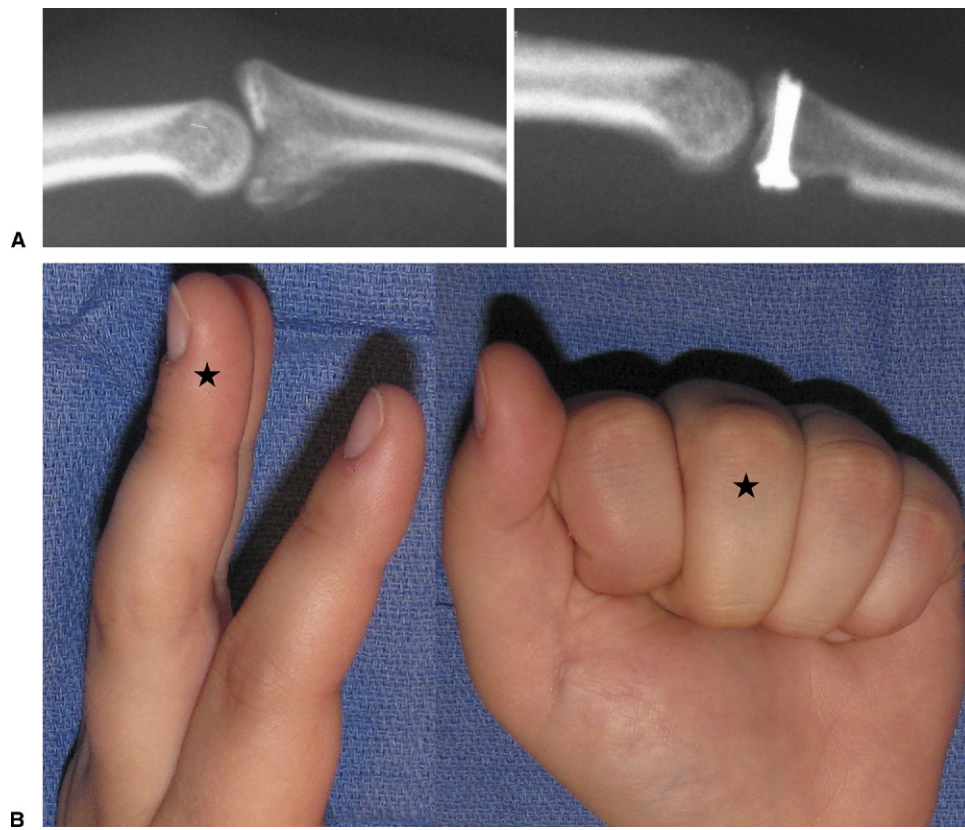
clinically stable to coronal and sagittal stress. Two-point discrimination was  $\leq 5$  mm on each injured digit except for 2 patients. One patient had 6-mm discrimination and 1 patient with a digital nerve injury from previous surgery remained at her baseline of 7 mm on the affected radial side. None of the patients who returned for a study evaluation demonstrated clinical evidence of carpometacarpal joint instability (Fig. 4).

The mean DASH score was 5 (range, 0–33). VAS-rated digital pain averaged 1.4 out of 10 and digital function 1.9 out of 10, with lower scores indicating superior outcomes. No patients reported pain at rest or pain preventing them from returning to their previous occupation or recreational activities. Of 20 patients, 10 reported mild cold intolerance in the digit and 2 noticed aching in the finger during factory work. Only 1 patient reported occasional mild aching over the donor hamate. No patients enrolled in the study had secondary procedures or subsequent tenolyses performed.

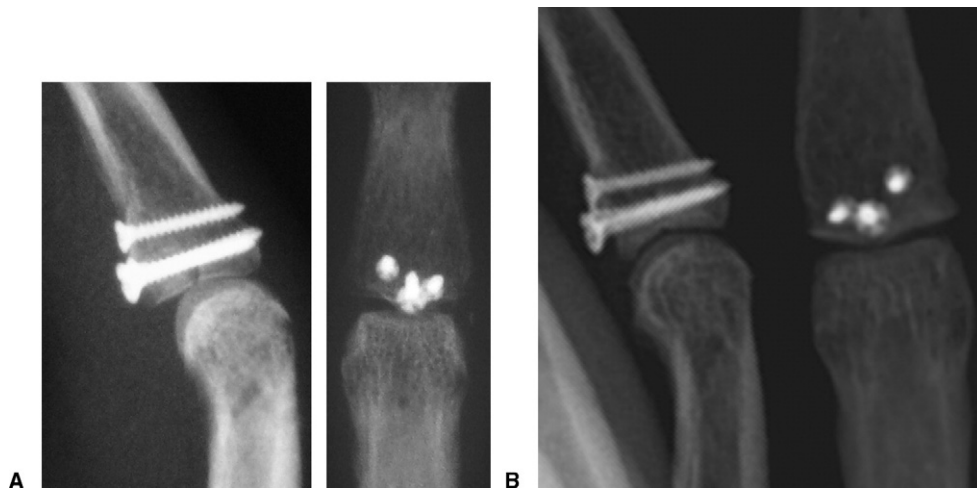The percentage of joint surface involvement did not correlate with outcome measures. Neither patient-rated outcome measures (DASH  $r < 0.1$ ,  $p = .9$ ; VAS pain  $r < 0.1$ ,  $p = .9$ ; VAS function  $r < 0.1$ ,  $p = .9$ ) nor objective measures (PIP extension  $r < 0.1$ ,  $p = .3$ ; PIP flexion  $r < 0.1$ ,  $p = .7$ ; DIP arc  $r = 0.2$ ,  $p = .9$ ; grip strength  $r = 0.3$ ,  $p = .3$ ) correlated significantly with the percentage of joint surface fractured.

A total of 14 patients had radiographs performed at a mean of 4.8 years (range, 1–7 years). Eight of these were acute reconstructions and 6 were chronic reconstructions. Of the 11 patients returning over 5 years after surgery, 8 were imaged. All grafts healed as judged by bridging trabecula. No grafts collapsed or demonstrated radiographic evidence of osteonecrosis. All joints remained located (Fig. 5). Of 14 joints, 6 had evidence of joint space narrowing. One of these had articular damage to the proximal phalanx noted at the time of arthroplasty. One patient had mild heterotopic bone formation around the joint, and retrocondylar bone formation was evident in 1 case.

Table 4 lists the outcomes of hamate reconstruction for acute versus chronic injuries. Chronic reconstructions achieved similar PIP arc of motion but trended toward poorer DASH scores ( $p = .06$ ). They were significantly more likely to demonstrate more residual digital pain ( $p < .05$ ) and regain less grip strength ( $p < .05$ ). In treating chronic injuries, hamate reconstruction



**FIGURE 4:** Patient injury radiograph and follow-up **A** radiograph and **B** clinical function at 7 years.



**FIGURE 5:** Anterior-posterior and lateral radiographs **A** postoperatively and **B** at 5 years, demonstrating concentric reduction and preservation of joint space in a 39-year-old man treated 4 weeks after injury.

increased mean PIP motion by 30° (range, loss of 20° to gain of 70°). All 4 patients with less than 45° of preoperative motion gained mobility (mean change, +54°), whereas 3 of the 4 patients with greater than 45° of preoperative motion lost mobility (mean change, -11°) (Table 5).

Five patients previously examined by Williams et al.<sup>10</sup> were re-examined in this study 5.5 years later (Table 6). We found VAS-rated pain was relatively stable, PIP arcs of motion changed minimally, and there were generally increased DIP arcs of motion.

**TABLE 4. Outcomes of Acute Versus Chronic Reconstructions**

Outcome	Acute (n = 14)	Chronic (n = 8)	p Value
PIP arc (°)	71	69	.75
DASH	2	9	.06
VAS for use	1.4	2.6	.17
VAS for pain	0.7	2.5	.04
Grip % contralateral	104	82	.01

### Complications

There were no infections or recurrent dislocations. Intraoperatively, one patient's dorsal cortex fractured, requiring fixation, and that same patient had clinical evidence of flexor pulley insufficiency postoperatively. In this series, we defined failure as unacceptable postoperative pain, alignment, or limited motion requiring revision surgery. We had 1 failure among this cohort. Postoperatively, the patient had a pain-free 90° PIP arc of motion but was dissatisfied with the 10° of ulnar deviation in the coronal plane. He reported having undergone a silicone arthroplasty at an outside institution. One additional patient in our series who had reconstruction 2 weeks after injury demonstrated a severe flexion contracture (80°) that allowed little PIP motion but was pain free. When examined, he volunteered that he had little interest in postoperative therapy, to which he attributed his stiffness.

### DISCUSSION

For the management of severe dorsal PIP fracture–dislocations, the hemi-hamate arthroplasty has several advantages over alternative treatments. Comminuted articular fractures prohibit, or at least increase, the technical difficulty of ORIF.<sup>12,13</sup> VPA is less reliable for fractures involving over 50% of the base of the middle phalanx.<sup>5,14</sup> External fixation, which relies on ligamentotaxis for indirect fracture reduction, is most effective acutely and requires pins that can be problematic from an infectious or functional standpoint.

This cohort represents a consecutive series of hemi-hamate arthroplasties performed in 1 hand specialty group. Although we have treated similar unstable dorsal PIP fracture–dislocations with VPA and ORIF, those patients currently offered ORIF or VPA in our group uniformly have less severe fractures. This practice trend developed after 2 previous critical evaluations of our surgeons' results of VPA and ORIF for this injury pattern. In 56 surgical PIP fracture–dislocations, 6

joints redislocated (3 VPA and 3 ORIF).<sup>6</sup> All redislocations involved over 50% of the joint surface. A second review of 9 PIP fracture–dislocations suggested ORIF was best suited for simple fractures as PIP motion decreased, as the number of fracture fragments increased (85° with 1 fragment and 65° with multiple fragments).<sup>8</sup>

As a result of these prior studies, patients with single fragment fractures amenable to internal fixation were not offered hemi-hamate reconstruction and are believed to be a population expected to recover with minimal disability. They are not thought to be an appropriate control when judging the outcomes of hemi-hamate arthroplasty. With the increased number of fracture fragments, ORIF may restore motion similar to that reported in our series. Therefore, the surgeon must decide whether fragment size is sufficient for reliable fixation or if debridement and placement of a hamate autograft would be technically more feasible. Patients presenting with more complex fracture patterns are offered VPA when fractures involve <50% of the joint surface. Hemi-hamate arthroplasty is recommended for fractures involving over half of the joint surface on the basis of our perceived risk of recurrent instability with VPA. Therefore, our practice has developed a selection bias toward hemi-hamate arthroplasty for the most extensive fractures, and left us with only a historical control cohort of VPAs performed by our surgeons for similar injuries. Our surgeons do not have any comparable current experience with dynamic external fixation for these injuries.

In the initial description by Hastings et al. in 1999, 5 patients were reported to have recovered 77° of PIP motion and 81% of contralateral grip strength at 10 months postoperatively (Hastings H, Capo J, Steinberg B, et al., presented at the 54th Annual Meeting of the American Society for Surgery of the Hand, 1999, Boston, MA). Williams et al. subsequently published results of 13 reconstructions at a mean of 16 months.<sup>10</sup> In that series, PIP motion averaged 85°, DIP motion was 60°, and grip strength was 80% of the opposite side. The average VAS pain level was 1.3 out of 10. Our patient cohort realized a more modest PIP arc of 70° with similar restoration of DIP motion (54°) and VAS pain ratings (1.4). Grip strength in our series more closely approximated contralateral strength (95%). Notably, the current cohort included more patients than both previous series and provided longer follow-up, at a mean of 4.5 years. By the patients' assessment, none of the reconstructed digits deteriorated in function or became more painful over time. Also, patients re-examined 5 years after the Williams et al.<sup>10</sup> study

**TABLE 5. Preoperative and Postoperative Motion in Chronic Reconstructions**

Patient	Preoperative PIP (°)	Postoperative PIP (°)	Δ PIP Arc (°)	Preoperative DIP (°)	Postoperative DIP (°)	Δ DIP Arc (°)
1	20–96	28–95	–9	0–50	0–65	15
2	10–75	30–90	–5	0–60	0–70	10
3	38–52	0–84	70	10–20	10–70	50
4	30–40	0–65	55	0–25	40–55	–10
5	35–65	0–95	65	10–30	12–60	18
6	0–45	5–105	55	0–45	10–70	15
7	0–45	20–45	–20	0–50	0–20	–30
8	20–50	30–85	25	10–10	0–70	70

Negative numbers indicate that there was a loss in the arc of motion between the pre- and postoperative measurements.

**TABLE 6. Change in Outcome Measures in Patients Reassessed 5 Years After the Williams et al.<sup>10</sup> Evaluation**

Patient	VAS Pain (0–10)	PIP Arc (°)	DIP Arc (°)
1	0.0→0.5	100→100	60→75
2	2.0→3.2	95→95	35→60
3	1.0→0.2	100→100	60→70
4	3.0→0.6	85→78	70→85
5	0.0→0.0	80→73	70→65
Mean	1.2→0.9	92→89	59→71

showed no marked decline in outcomes. However, 2 of these patients lost 7° each of PIP motion, whereas 3 fully maintained their PIP mobility. We believe that the more restricted PIP motion in this series is a function of increased cohort size and more accurately reflects the mean result of this procedure as opposed to deterioration over time. However, a larger number of patients will need to be examined serially over time to validate this statement statistically and demonstrate the long-term durability of this reconstruction.

Our radiographic evaluation demonstrated loss of joint space in 43% of patients. At this duration of follow-up, we could not correlate radiographic changes with poorer outcomes. Of the 4 patients with perfect DASH scores, 3 had evidence of joint space narrowing. For the 6 patients with loss of joint space, the average VAS pain score was 1.0, which was below the mean for the entire cohort. We acknowledge that these are relatively young patients; anticipating many years of future use, it is too early to determine the long-term implications of this joint space narrowing.

Our outcomes compare favorably with recent series

of PIP fracture–dislocations treated by alternative methods (Table 7). Ellis et al. reported 4 patients with fractures of 50% of the articular surface that regained 88° of PIP motion with external fixation.<sup>3</sup> This superior result is limited by the fact that, although none of these 4 patients studied had flexion contracture, 5 of the 6 patients lost to follow-up had flexion contractures averaging 21°. The authors were unable to identify any series of VPA in which the results of patients with fractures of over 50% of the joint surface could be specifically extracted.

Restoration of PIP motion was similar between acute and chronic reconstructions. The patient-rated outcome measures demonstrated functional digits in the chronic injuries despite indicating less optimal ratings than acute injuries (chronic vs acute: DASH 9 vs 2, VAS digital function 2.6 vs 1.4, and VAS digital pain 2.5 vs 0.7). We believe that each of these measures would reach statistical significance with a larger cohort. However, the clinical impact of the differences in the mean performance on these measures is critical. A 7-point differential on the DASH or less than 2.0 differential on a VAS rating would be difficult to detect clinically.<sup>15</sup> In our 8 patients treated for chronic injuries, all patients returned to work and were functioning well. Of these 8 patients, 3 noted some dissatisfaction with their result. However, each patient had a different factor behind his answer: difficulty with active flexion, 30° extension contracture, and aching in the digit after full days of manual labor. Therefore, no single shortcoming was evident in chronic reconstructions. The 5 other patients with chronic injuries reported full satisfaction with the surgery and demonstrated objective measures equal to any acute reconstruction. This series suggests that outcomes of chronic reconstructions, although potentially

**TABLE 7. Outcomes of PIP Fracture–Dislocations Involving at Least 50% of Articular Surface**

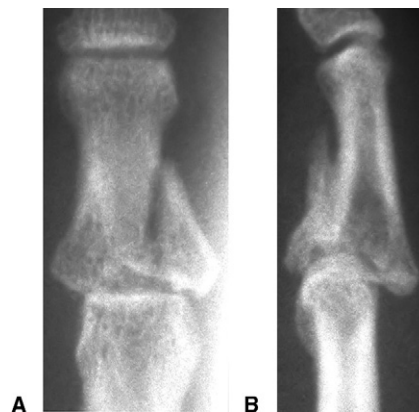Study	% Joint Involved	Treatment	PIP Range of Motion (°)	Grip
Ellis et al. <sup>3</sup> (n = 4)	50%	External fixation	0–88	84%
Lee et al. <sup>13</sup> (n = 5)	≥50%	ORIF	12–98	NA
Zemel et al. <sup>16</sup> (n = 13)	62%	Osteotomy	14–87	NA
Hamilton et al. <sup>8</sup> (n = 9)	62%	ORIF	15–84	45 kg
Current study	63%	Hamate	19–89	95%

NA, not available.

equal to those of acute injuries, are likely to be slightly more modest.

This study was limited by the number of patients treated with hemi-hamate arthroplasty. Small case series are prone to the influence of outliers on the mean and tend to be underpowered for detailed statistical patient subgroup analysis. In evaluating acute and chronic reconstructions, we defined a clinically significant difference in visual analog scores for pain or function as 2.0 (scale, 0–10). For 80% power with  $\alpha = 0.05$ , we would need 26 patients per group to delineate differences in digit use. Provided that this number of patients would not be available in the near future, we have proceeded with the study acknowledging this deficiency and taking care to point out statistical trends likely to become statistically significant in a larger series. Of additional concern in this retrospective series is whether those unable to be examined bias our results. The patients either lost to follow-up or unable to be examined in our series were younger and slightly farther removed from surgery, but based on the data presented in Table 1, we believe that it is unlikely that the loss of these patients has biased our results in a positive direction.

Two patients who have undergone hemi-hamate arthroplasty in our practice were excluded because their injuries represented an expanded indication for the reconstruction. Both patients presented with PIP fracture–dislocations with diaphyseal fracture extension (Fig. 6). The first patient was a 55-year-old woman whose treatment was complicated by incompetence of the flexor digitorum superficialis and postoperative fracture through the thin dorsal metaphyseal–diaphyseal junction. The patient healed with dorsal PIP subluxation, resulting in a pain-free but essentially motionless PIP joint. The second patient was a 45-year-old woman whose injury necessitated that the relatively flat hemi-hamate graft reconstitute nearly the entire middle phalangeal articular surface. The PIP joint subluxed and was treated subsequently with a VPA and FDS tenode-



**FIGURE 6:** A Anteroposterior and B lateral radiographs of PIP fracture–dislocation with diaphyseal extension.

sis. This resulted in a painless, auto-ankylosed joint. Thus, these complex injuries represent a fracture pattern that we have yet to treat successfully with a hemi-hamate autograft; we would give strong consideration to alternative treatment methods in these situations.

Although this case series is not large enough to statistically analyze patient factors predictive of surgical success or failure, we have learned several lessons. Chronic PIP fracture–dislocations are reconstructible by hemi-hamate autografts. We cannot exactly define the upper limit of joint involvement that can be reconstructed; however, as the dorsal articular surface becomes smaller, it is at risk for fracture, and it did fracture in our one patient with 90% joint involvement. Furthermore, the amount of remaining dorsal bone can be overestimated preoperatively if sagittal fracture lines that substantially narrow the intact cortex are not appreciated. In addition, although the distal hamate articular surface matches that of the middle phalanx well in the coronal plane, it has a much larger sagittal radius of curvature.<sup>16</sup> Therefore, it cannot be relied on to recreate the entire articular surface, but rather must be positioned canted toward the joint to restore the volar buttress.

The results of hemi-hamate reconstructions for severe dorsal PIP joint fracture–dislocations are promising. Patients do not regain full motion, but a PIP arc of 70° with an average of 89° of flexion appears to impart minimal functional limitation. In our practice, the hemi-hamate arthroplasty is the treatment of choice for acute and chronic PIP fracture–dislocations involving at least 50% of the volar articular surface that are not amenable to primary internal fixation.

## REFERENCES

1. Kiefhaber TR, Stern PJ. Fracture dislocations of the proximal interphalangeal joint. *J Hand Surg* 1998;23A:368–380.
2. Hastings H, Carroll C. Treatment of closed articular fractures of the metacarpophalangeal and proximal interphalangeal joints. *Hand Clinics* 1988;4:503–527.
3. Ellis SJ, Cheng R, Prokopis P, Chetboun A, Wolfe SW, Athanasian EA, et al. Treatment of proximal interphalangeal dorsal fracture-dislocation injuries with dynamic external fixation: a pins and rubber band system. *J Hand Surg* 2007;32A:1242–1250.
4. Ruland RT, Hogan CJ, Cannon DL, Slade JF. Use of dynamic distraction external fixation for unstable fracture-dislocations of the proximal interphalangeal joint. *J Hand Surg* 2008;33A:19–25.
5. Eaton RG, Malerich MM. Volar plate arthroplasty of the proximal interphalangeal joint: a review of ten years' experience. *J Hand Surg* 1980;5:260–268.
6. Deitch MA, Kiefhaber TR, Comisar BR, Stern PJ. Dorsal fracture dislocations of the proximal interphalangeal joint: surgical complications and long-term results. *J Hand Surg* 1999;24A:914–923.
7. Dionysian E, Eaton RG. The long-term outcome of volar plate arthroplasty of the proximal interphalangeal joint. *J Hand Surg* 2000;25A:429–437.
8. Hamilton SC, Stern PJ, Fassler PR, Kiefhaber TR. Mini-screw fixation for the treatment of proximal interphalangeal joint dorsal fracture-dislocations. *J Hand Surg* 2006;31A:1349–1354.
9. Keramidas E, Solomos M, Page RE, Miller G. The Suzuki frame for complex intra-articular fractures of the proximal interphalangeal joint of the fingers. *Ann Plast Surg* 2007;58:484–48.
10. Williams RM, Kiefhaber TR, Sommerkamp TG, Stern PJ. Treatment of unstable dorsal proximal interphalangeal fracture/dislocations using a hemi-hamate autograft. *J Hand Surg* 2003;28A:856–865.
11. Hudak PL, Amadio PC, Bombardier C. Development of an upper extremity outcome measure: the DASH (disabilities of the arm, shoulder and hand). The Upper Extremity Collaborative Group (UECG). *Am J Ind Med* 1996;29:602–608.
12. Lee JY, Teoh LC. Dorsal fracture dislocations of the proximal interphalangeal joint treated by open reduction and interfragmentary screw fixation: indications, approaches and results. *J Hand Surg* 2006;31B:138–146.
13. Grant I, Berger AC, Tham SK. Internal fixation of unstable fracture dislocations of the proximal interphalangeal joint. *J Hand Surg* 2005;30B:492–498.
14. Ishida O, Ikuta Y. Results of treatment of chronic dorsal fracture-dislocations of the proximal interphalangeal joints of the fingers. *J Hand Surg* 1998;23B:798–801.
15. Goldfarb CA, Gelberman RH, McKeon K, Chia B, Boyer MI. Extra-articular steroid injection: early patient response and the incidence of flare reaction. *J Hand Surg* 2007;32A:1513–1520.
16. Capo JT, Hastings H, Jr, Choung E, Kinchelov T, Rossy W, Steinberg B. Hemicondylar hamate replacement arthroplasty for proximal interphalangeal joint fracture dislocations: an assessment of graft suitability. *J Hand Surg* 2008;33A:733–739.